

Rechtsherzerkrankungen

Funktionsanalyse des rechten Ventrikels

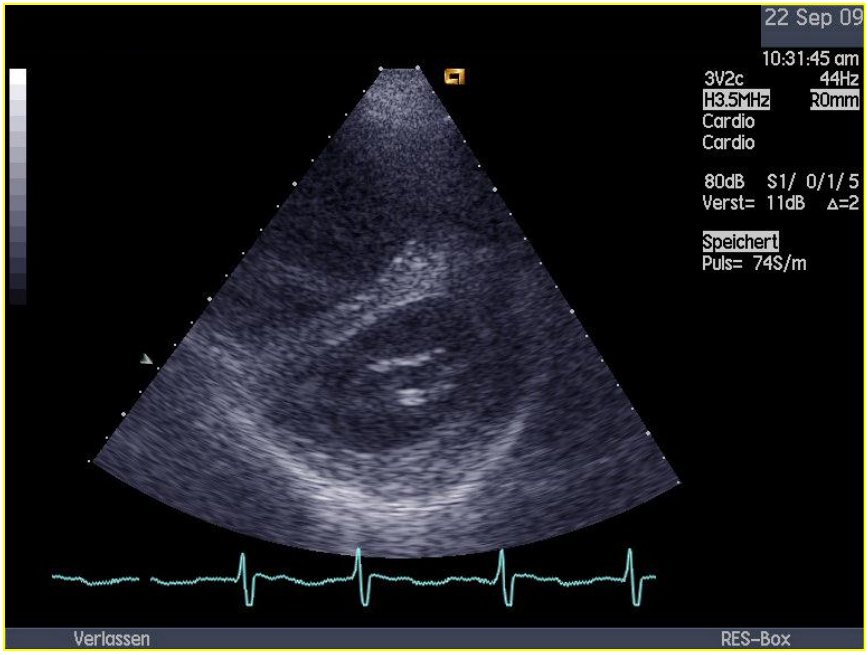

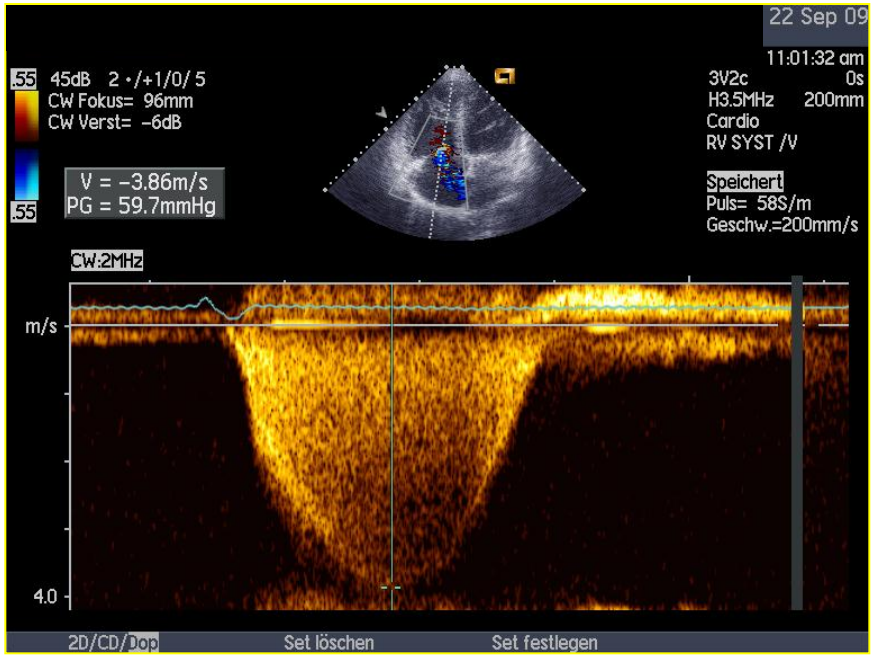

Größenbestimmung des RV in der Enddiastole

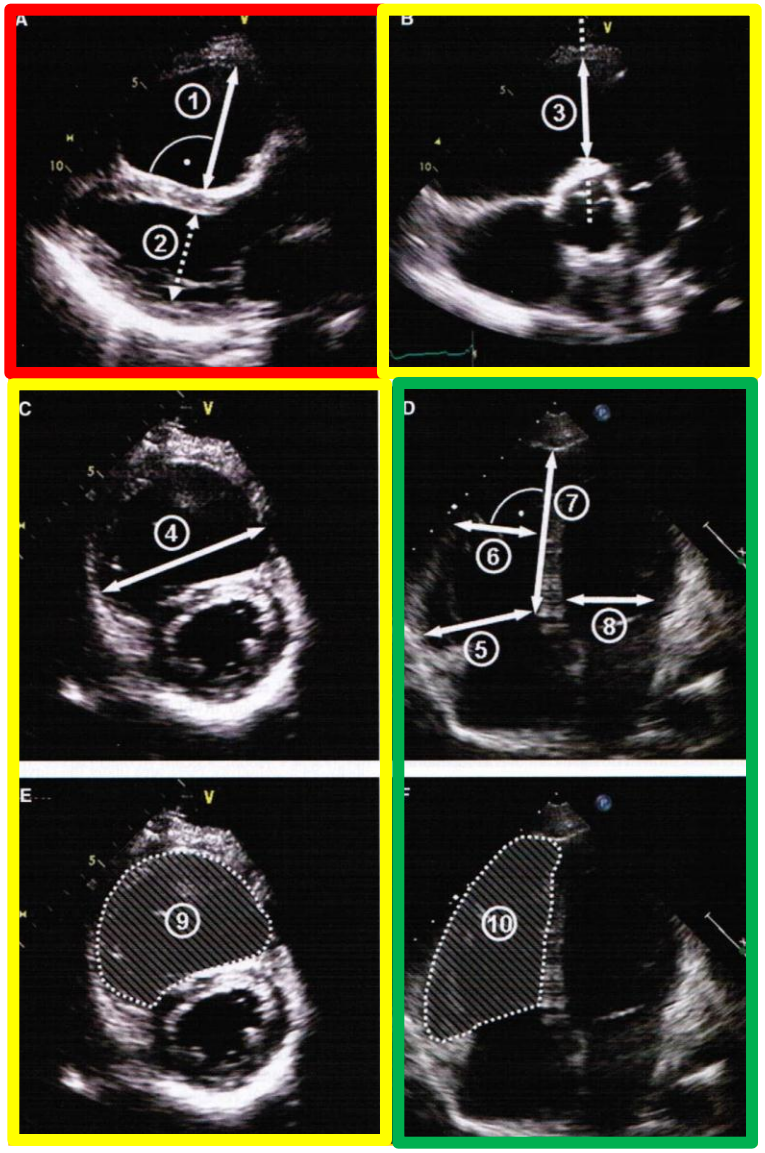

Parasternal lange Achse

Parasternal kurze Achse

Apikaler 4-Kammerblick

Greutmann M et al. J Am Soc Echocardiogr 2010; 23: 905-11
Lai WW et al. Int J Cardiovasc Imaging 2008; 24: 691-8

Evaluierung der systolischen RV-Funktion

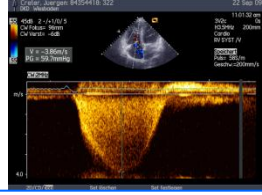

TAPSE = **T**ricuspid **A**nnular **P**lane **S**ystolic **E**xcursion

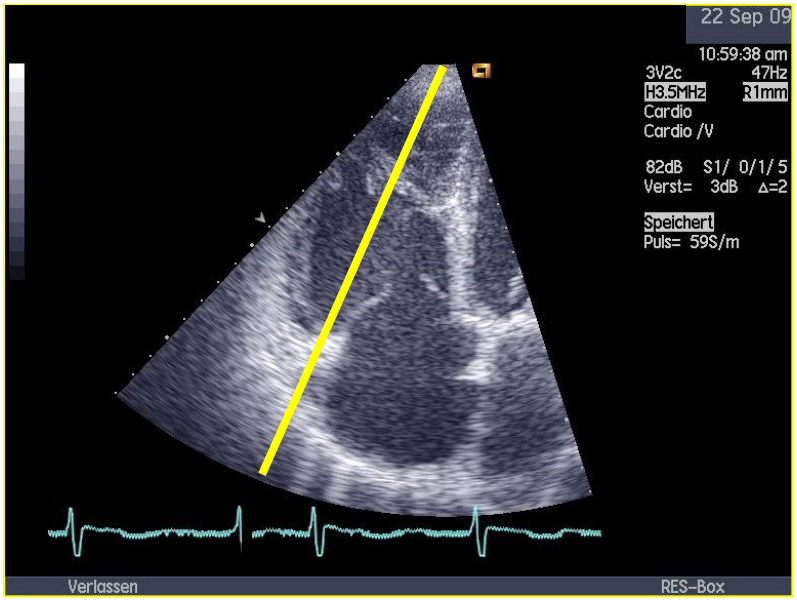

AP 4CV

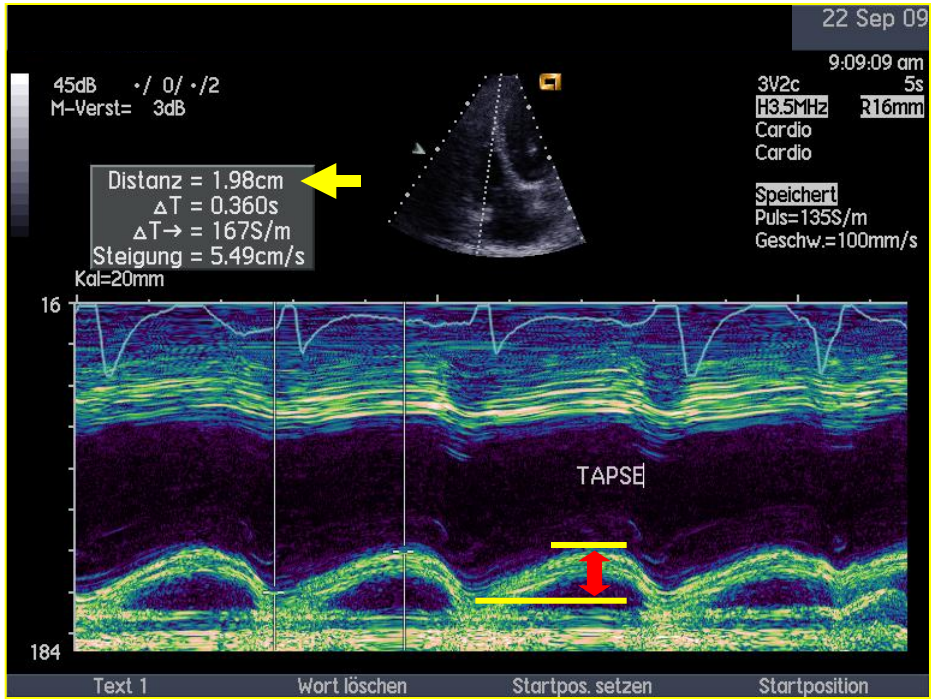

Normwert > 18 mm
Pathologisch < 15 mm

Evaluierung der systolischen RV-Funktion

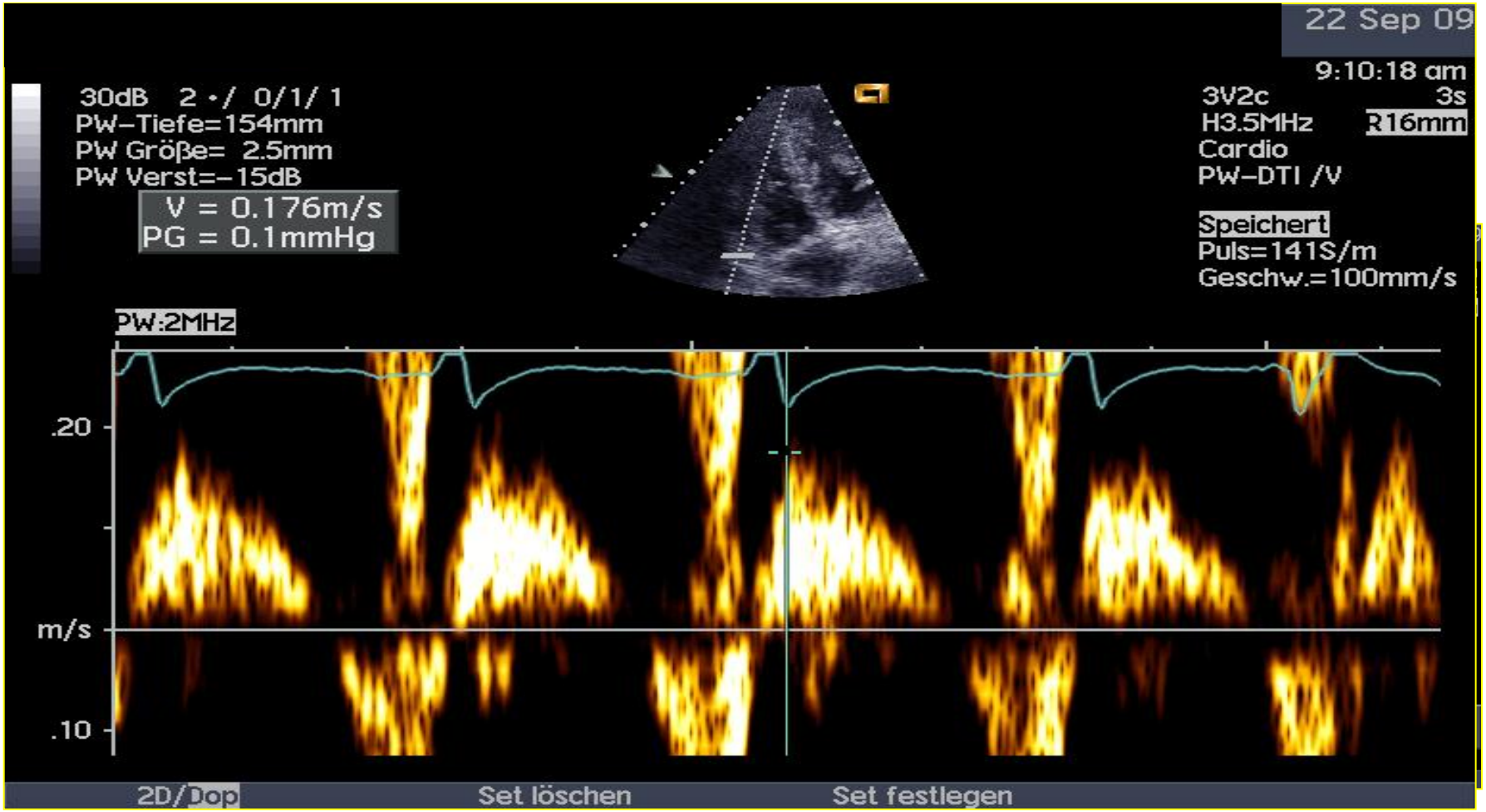

Normwert
TDI-TVA > 11 +/- 2 cm/s

Gewebedoppler

RV-Funktion

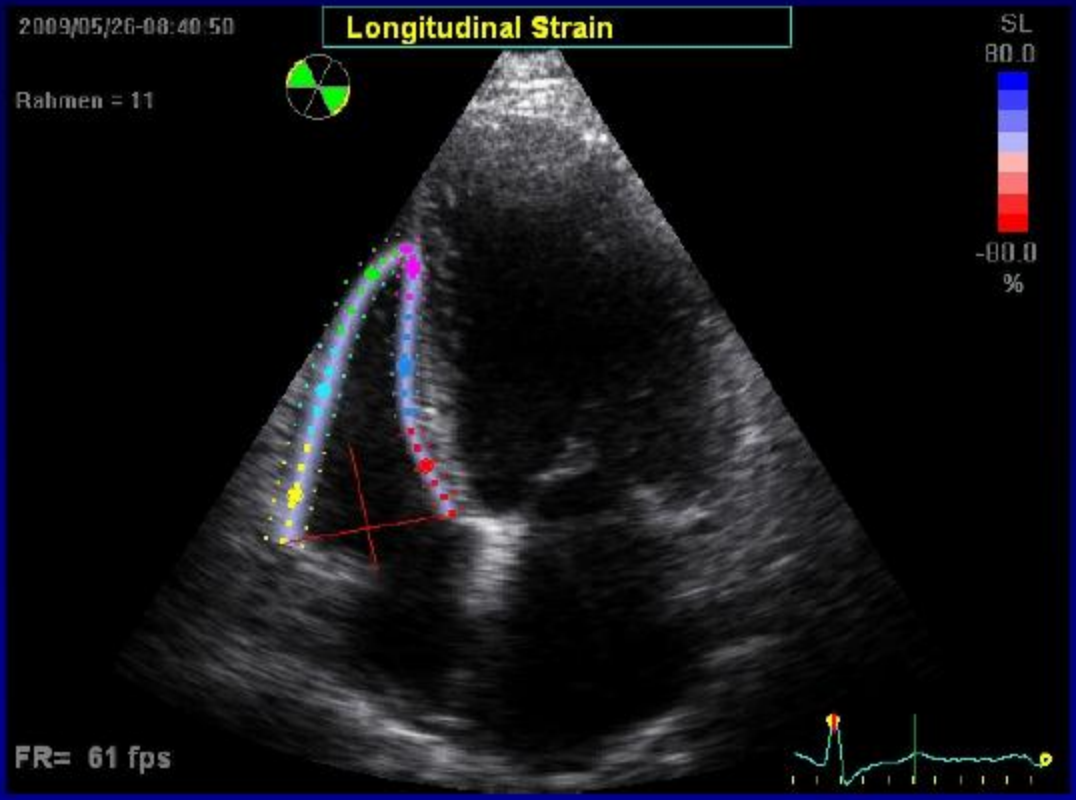

- **Fractional area change 32-60%**
- **TAPSE: 2 ± 0.3 cm**
- **max.Gewebegeschw. d.Basis d.freien RV-Wand: 11 ± 2.1 cm/s**

Kukulski JASE 2000;13:194

Rechtsherzerkrankungen



Regionale Funktionsanalyse des rechten Ventrikels

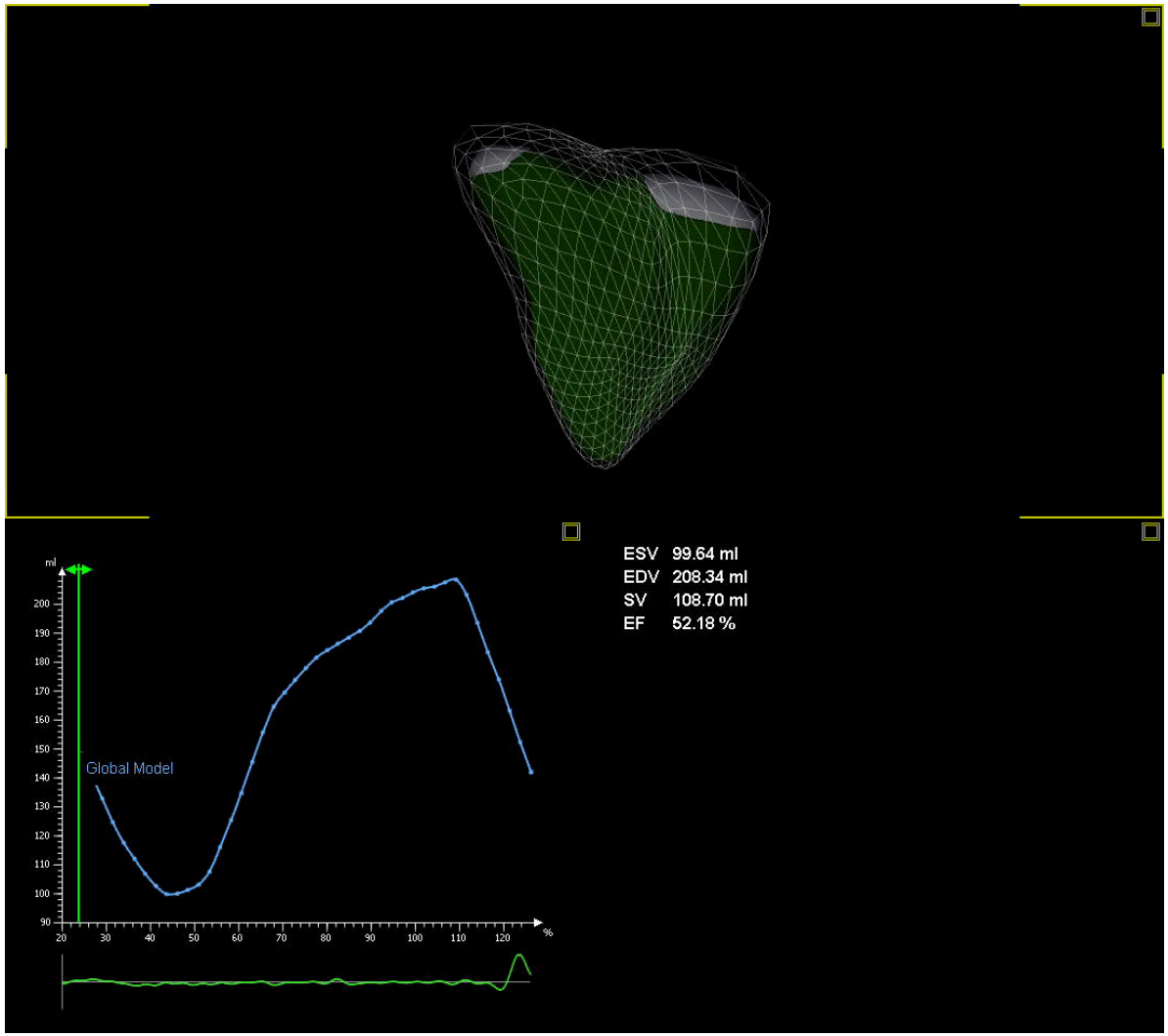

Definition der pulmonalen Hypertonie

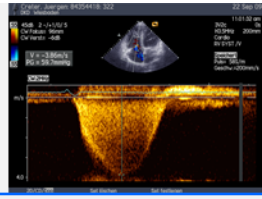

Weltkonferenz in Dana Point 2007

Die pulmonale Hypertonie (PH) ist definiert durch einen mittleren pulmonalarteriellen Druck > 25-30 mmHg in Ruhe.

(alternativ: systolischer PA Druck > 35 mmHg)

und/oder > 30 mmHg unter Belastung bei einem normalen pulmonalarteriellen Verschlussdruck von < 15 mmHg.

Die Überschreitung eines pulmonalvaskulären Widerstandes (PVR) > 3 Wood-Einheiten (WU) wird als Widerstandserhöhung definiert; dies ist Ausdruck einer zunächst reversiblen, später irreversiblen („fixierten“) pulmonalarteriellen Vaskulopathie.

Pulmonalarterielle Hypertonie (PAH)

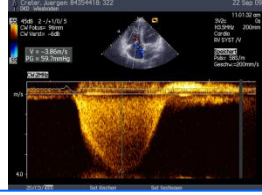

Echokardiographische Erfassung

Morphologie (2D-Echo)

1. RV/RA- und PA-Dilatation
2. RV-Hypertrophie
3. Paradoxe Septumbewegung
4. Eingeschränkte RV-Funktion
5. IAS Ballonierung nach links
6. VCI, CVS und Lebervenen dilatiert

PA-Druckabschätzung - systolisch

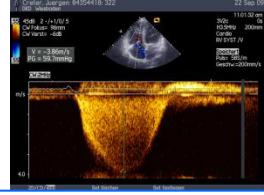

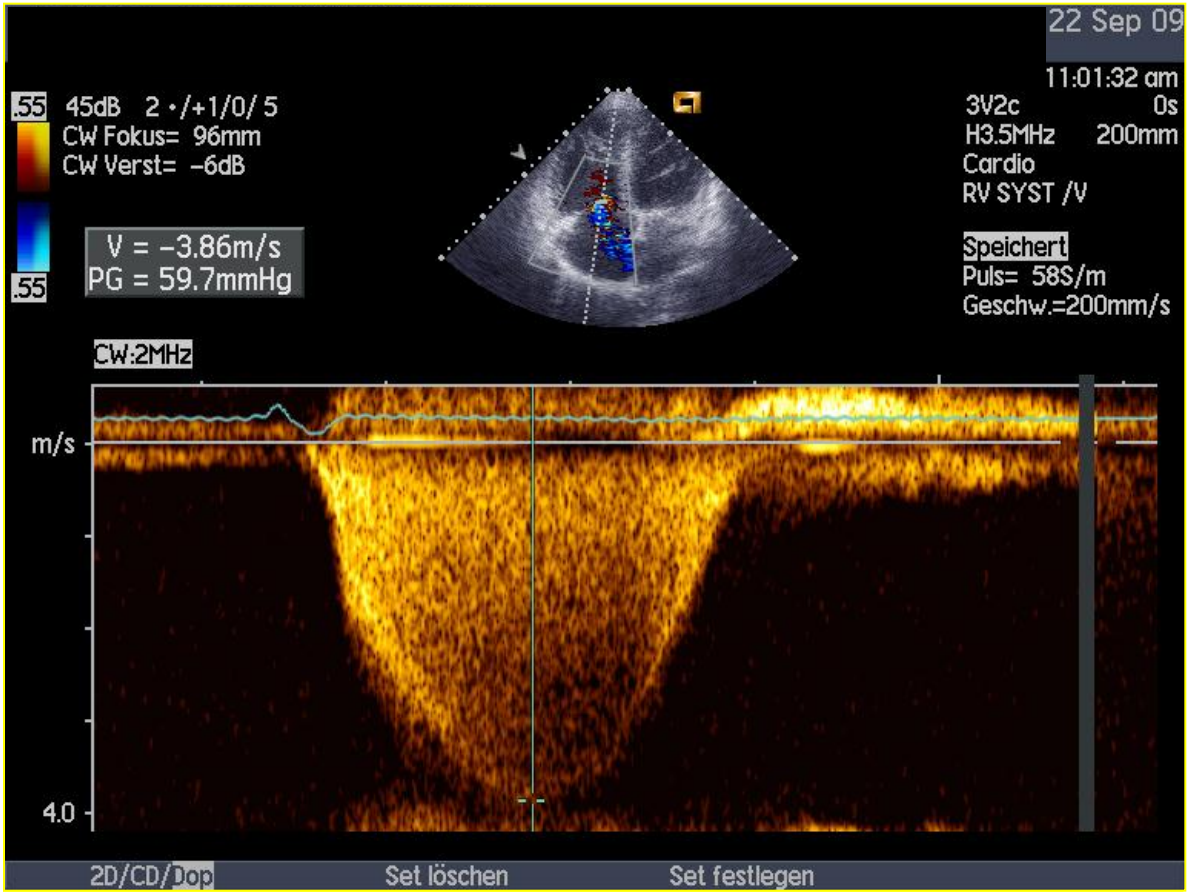

Voraussetzung:
Keine Pulmonalstenose

$$SPAP = 4xV_{TRmax}^{2} + RAP$$

PA-Druckabschätzung - diastolisch

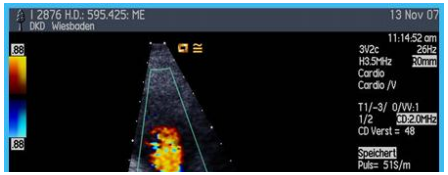

Circulation

JOURNAL OF THE AMERICAN HEART ASSOCIATION

American Heart Association®

Learn and Live℠

Continuous-wave Doppler echocardiographic detection of pulmonary regurgitation and its application to noninvasive estimation of pulmonary artery pressure

T Masuyama, K Kodama, A Kitabatake, H Sato, S Nanto and M Inoue

Circulation 1986;74;484-492

Circulation is published by the American Heart Association. 7272 Greenville Avenue, Dallas, TX 72514

Copyright © 1986 American Heart Association. All rights reserved. Print ISSN: 0009-7322. Online ISSN: 1524-4539

pressure. Circulation 1986;74:484-92.

PA-Druckabschätzung - diastolisch

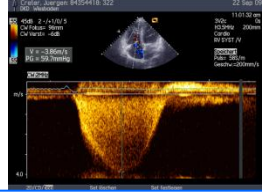

PA diast = 4 x $(2{,}03)^2$ + ZVD = 26 mmHg

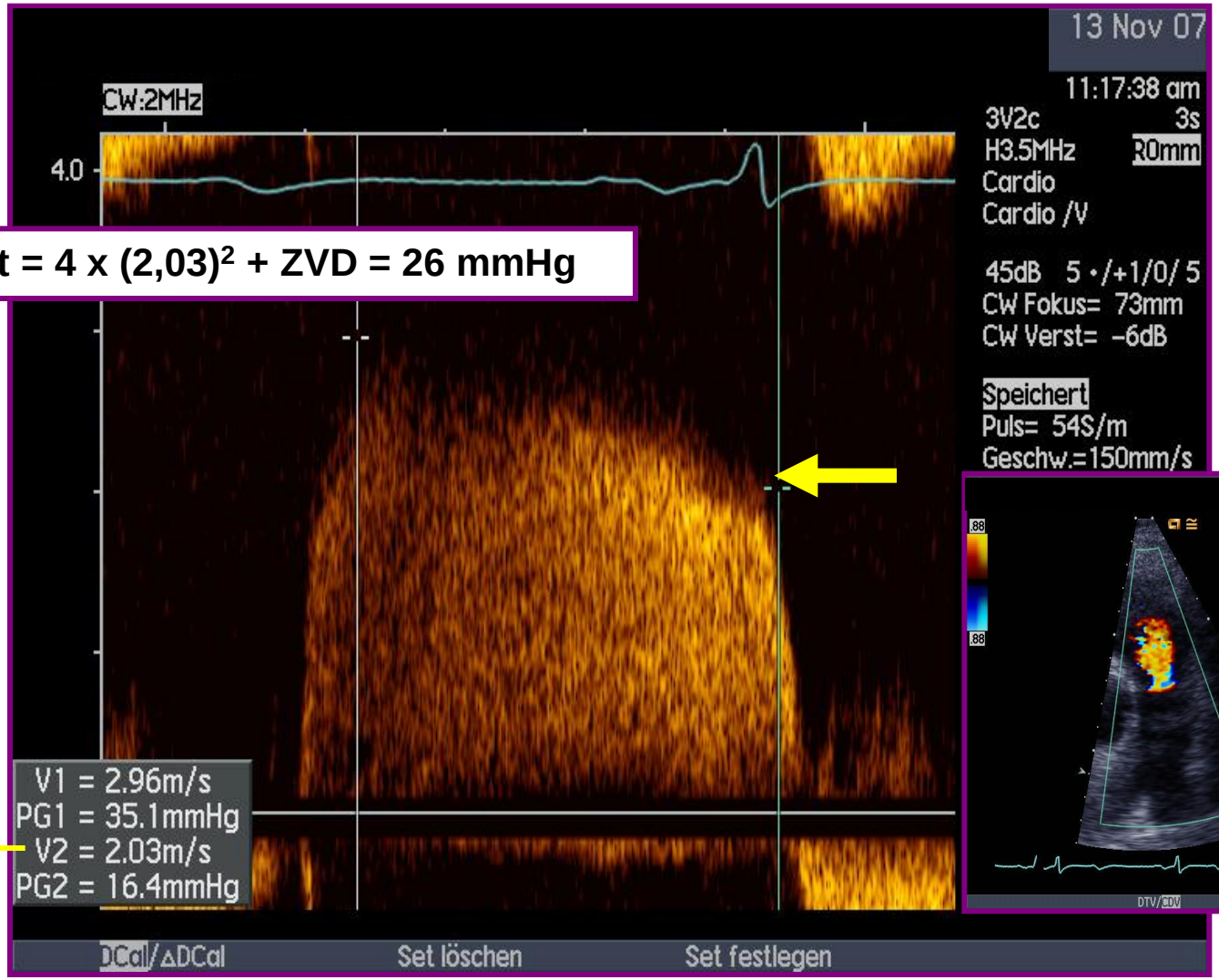

RV-Ausstrom-Akzelerationszeit (AT)

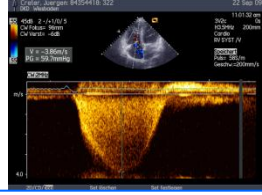

AT korreliert mit dem mittleren PA-Druck (mPAP)

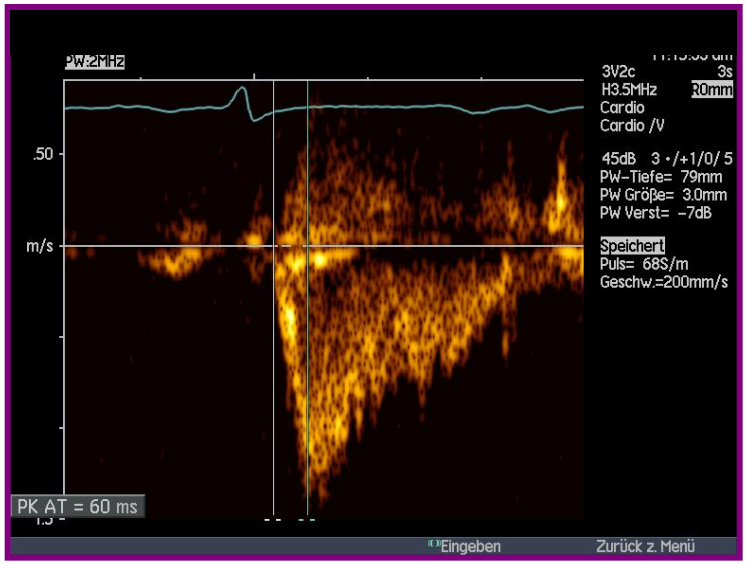

Akzelerationszeit	pulmon. Hypertonie	geschätzter mPAP
100 ms	keine	< 20 mm Hg
70-90 ms	leichte	20-30 mm Hg
50-70 ms	mittelgradige	30-40 mm Hg
< 50 ms	schwere	> 40 mm Hg

Rechtsatriale Druckabschätzung

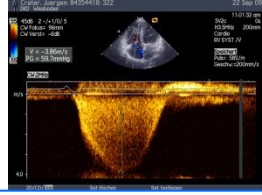

Beurteilung des Füllungszustandes und der Atemmodulation der V. cava inferior

V. cava inf.	Atemmodulation	*geschätzter* RAP
< 20 mm	kompletter Kollaps	(0 -) 5 mm Hg
± 20 mm	Abnahme > 50 %	(5 -) 10 mm Hg
± 20 mm	Abnahme < 50 %	(10 -) 15 mm Hg
> 20 mm	Abnahme < 50 %	(15 -) 20 mm Hg
> 25 mm und Dilatation Lebervenen	keine Änderung	> 20 mm Hg

nach: Lee et al. Echocardiographic assessment of right heart hemodynamic parameters. J Am Soc Echocardiogr 2007;20:773-782

Pulmonalvaskulärer Widerstand (PVR)

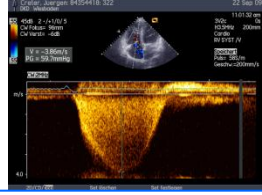

$$\text{PVR (WU)} = \frac{\text{TRV(m/s)}}{\text{RVOT VTI (cm)}} \times 10$$

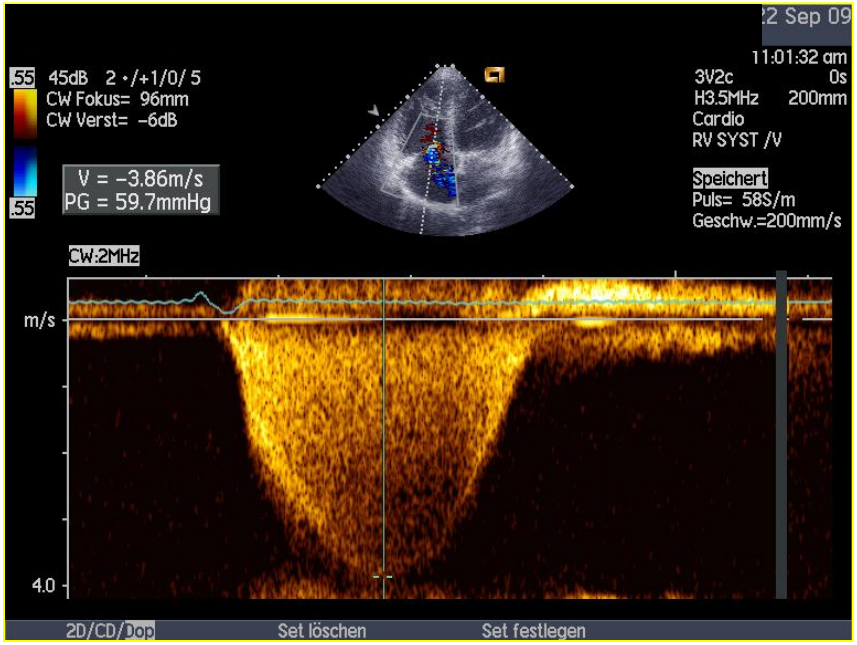

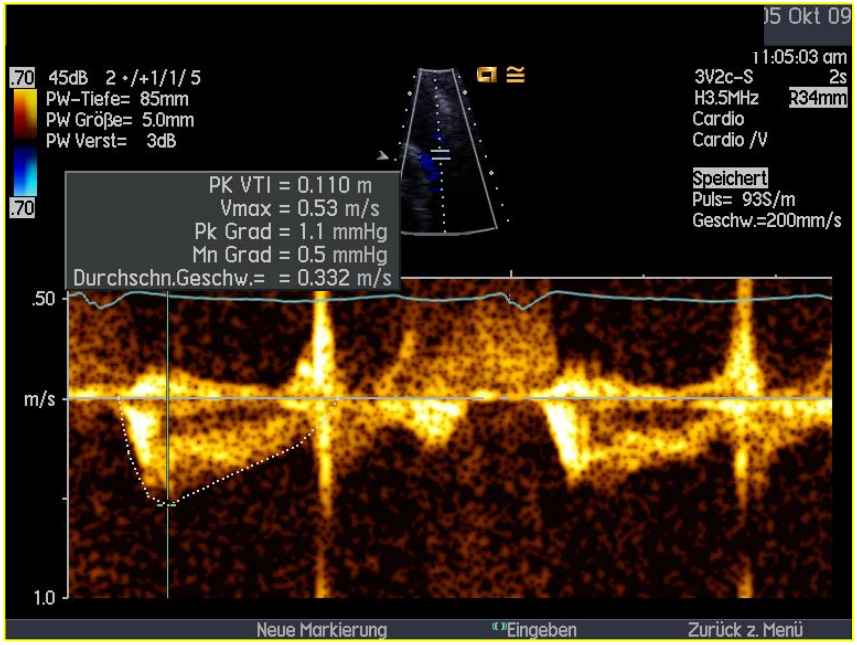

Normwert (PVR): < 2,0 Wood units (WU)

Rechtsherzerkrankungen



Funktionsanalyse des rechten Ventrikels

Klinisch bewärt haben sich:

- TAPSE
- PA-Druck-Bestimmung
  - Systolisch
  - Diastolisch
  - Mitteldruck
- AT des Pulmonalflusses
- PA-Widerstandsbestimmung
- 3D-Erfassung des RV